



Date : 1393/11/13

Patient's Name : Ahmad Mirzavand

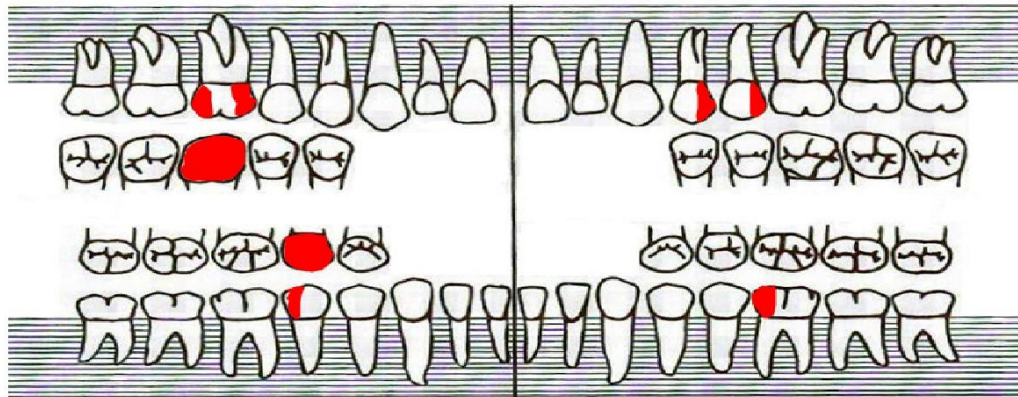
Doctor's Name : Dr. Flora Hashemi

Report Type : Panoramic & BiteWing

Age : 26 yo / Male



Deep Caries.....



Periapical Lesion(s)

6

5

Remained Root(s).....

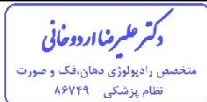8

Impacted Teeth..... Negative

Maxillary Sinus..... Normal

Periodontal Status..... Caculus Formation is seen.

Other



Sincerely
Dr. Alireza Ordoukhani
Oral & Maxillofacial Radiologist